

THE PROXIMAL END OF THE FEMUR: EXPLORING ITS CLINICAL SIGNIFICANCE, IMPLICATIONS IN ORTHOPEDICS

Jolly Agarwal¹, Anjali Sharan², M. K Pant³

¹Associate Professor, Department of Anatomy, Government Doon Medical College, Uttarakhand, India.

²Post graduate, Department of Anatomy, Government Doon Medical College, Uttarakhand, India.

³Professor and Head, Department of Anatomy, Government Doon Medical College, Uttarakhand, India.

Received : 06/08/2023
Received in revised form : 05/09/2023
Accepted : 18/09/2023

Keywords:
Distance, femur, head, prosthesis, trochanter

Corresponding Author:
Dr. Jolly Agarwal,
Email: drjolly21177@gmail.com

DOI: 10.47009/jamp.2023.5.5.231

Source of Support: Nil,
Conflict of Interest: None declared

Int J Acad Med Pharm
2023; 5 (5); 1175-1178



Abstract

Background: The femur has a proximal end, shaft, and distal end. The proximal end consists of the head, neck, and greater and lesser trochanter. The head of femur forms hip joint with cup-shaped acetabulum. The neck-shaft angle facilitates movement at the hip joint, enabling the limb to swing and provide lever for the action of the muscles. The aim of present study is to provide and add data of head of femur for proper size implant and prosthesis in arthroplasties of hip joint so that these surgeries are more successful and there will be less chance of complication. Such type of study is not done in Garhwal region. **Materials and Methods:** The following parameters of upper end of femur were measured – Vertical and transverse diameter of head, length and width of neck, distance between greater and lesser trochanter, neck shaft angle and surgical neck diameter. The mean and standard deviation were calculated. **Result:** The mean vertical diameter of head of femur is 40.89 ± 4.26 mm and mean transverse diameter of head is 37.96 ± 4.20 mm. The mean length and width of neck is 37.96 ± 4.20 mm, 26.14 ± 4.56 mm respectively. The mean neck shaft angles is $129.03^\circ \pm 6.53$. The p-value and correlation between the vertical diameter of right and left side of femoral head was statistically significant ($r=0.42$ & p-value 0.01) and also width of right and left side of femur was also statistically significant ($r=0.58$ & p-value 0.0007). **Conclusion:** The findings of present study showed that there is a racial and regional variation in parameters of upper end of femur. The present study also provides data for implant and prosthesis of head of femur for arthroplasties of hip joint.

INTRODUCTION

The head of femur and cup-shaped acetabulum form multiaxial spheroidal hip joint [1]. The femur, the longest and strongest bone in the body, holds great clinical significance in the world of anatomists, forensic experts, orthopaedic surgeons, and sports physicians. The length of the femur is associated with a striding gait and its strength with the weight and muscular forces it is required to withstand. The femur has a proximal end, shaft, and distal end. The proximal end consists of the head, neck, and greater and lesser trochanter. The spheroidal head of the femur articulates with the acetabulum of the hip bone to form the hip joint and lies within the joint capsule.^[1] The neck-shaft angle facilitates movement at the hip joint, enabling the limb to swing clear of the pelvis. The neck also provides a lever for the action of the muscles acting about the hip joint, which are attached to the proximal femur. A wide femoral neck is found to be associated with

an increased risk of hip fractures in the elderly.^[2] Acetabulum is a hemispherical cavity on the medial part of the hip joint. An operation on the proximal femur is one of the commonest in orthopedic surgical practice. The strength of joint by bony support is a necessity in the hip therefore; there is deep articulation with consequent limitation of movements. Thorough knowledge of hip joint anatomy is important to understand its biomechanics.

The anthropometry of the proximal femur and acetabulum holds great clinical significance in designing implants and prosthesis for femoral fractures and hip joint arthroplasty.^[3,4] Surgical fixation with a properly matched prosthesis plays a crucial role in improving long-term treatment outcomes and preventing post operative complications such as osteolysis with aseptic conditions and may cause improper load distribution, discomfort, micromotion of the implanted stem, and stress shielding.^[5]

Therefore, the aim of present study is to provide data of head of femur for proper dimensions of implant and prosthesis in arthroplasties of hip joint so that these surgeries are more successful and there will be less chance of complication. Regional and racial variation in parameters of morphometry of proximal head of femur is also present. And such type of study is not done particularly in Garhwal region therefore; this data may provide insight for prosthesis, implant for proximal end of femur in Garhwal region.

MATERIALS AND METHODS

The present study is observational and cross-sectional type of study. The sample size is calculated by purposive sampling. This study was conducted on 60 dry adult femur bones from museum. Out of these bones, 30 were of right side and 30 bones were of left side. The fractured bones and bones with visible deformity were excluded from study. The age and sex of bones were not known. The different parameters of upper end of femur were observed and measured.

The following parameters of proximal femur were measured with the help of digital vernier calipers as follows^[3,4] -

1. Vertical diameter of head- Distance in between the upper and lower end of the femoral head in the craniocaudal axis.
2. Transverse diameter of head- It is measured as maximum transverse diameter.
3. Length of neck- The distance between midpoints at the base of the femoral head to midpoint of the intertrochanteric line.
4. Width of neck- The thickness of the neck of the femur perpendicular to length of neck.
5. Surgical diameter- The diameter at the base of femoral head
6. Distance between lesser and greater trochanter
7. Neck shaft angle- It is defined as the angle between the axis of the neck and the axis of the shaft of the femur.

To reduce the error every measurement is taken three times by same person and their average is taken. The mean, standard deviation, Pearson correlation value (<0.05 is significant) were calculated. The measurements were taken in millimeters. Ethical clearance was obtained for the study from Institutional Ethical Committee with reference number "GD/MEC/2020/101.

RESULTS

The mean vertical diameter of head of femur is 40.89 ± 4.26 mm and mean transverse diameter of head is 37.96 ± 4.20 mm. The mean length and width of neck of femur are 37.96 ± 4.20 , 26.14 ± 4.56 respectively. The mean distance between greater and lesser trochanter is 53.67 ± 7.19 mm. The mean neck

shaft angles is $129.03^\circ \pm 6.53$ and mean surgical neck diameter is 32.05 ± 4.61 mm.

The maximum vertical and transverse diameters of head are 48.34mm and 23.59mm respectively while minimum vertical and transverse diameter is 49.12mm and 25.11mm respectively. The maximum length and width of neck of femur is 35.75 and 34.77mm while minimum is 18.79 and 16.59 mm. The maximum and minimum distance between greater and lesser trochanter are 73.89 mm and 29.63 mm. The maximum and minimum neck shaft angle is 143° and 105° . The maximum and minimum surgical neck diameter are 44.54 mm and 24.82 mm [Table 1&Figure 1].

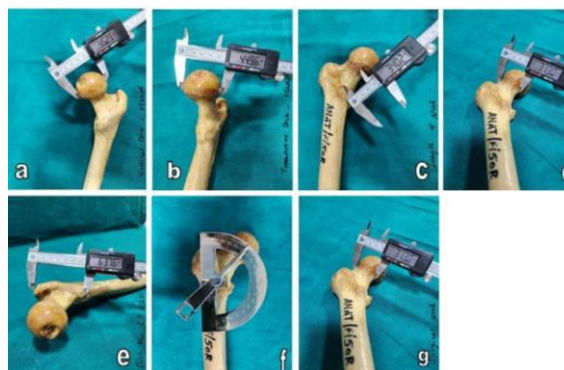


Figure 1: Showing different parameters of upper end of femur (a) horizontal diameter of head (b) vertical diameter of head (c) length of neck (d) width of neck (e) Intertrochanteric length (f) Neck-shaft angle (g) Surgical neck diameter

[Table 1]: Showing different parameters of right and left side of upper end of femur

The mean vertical head diameter (41.05 ± 3.98) mm of left side is more as compare to right side (40.65 ± 3.6) mm, while mean transverse head diameter of right side (38.24 ± 4.05) mm is more as compare to left side (37.32 ± 3.91) mm. The length of neck of femur is more on right (26.2 ± 4.52) mm side as compare to left side (25.76 ± 4.69) mm while width of neck of femur is more on left side (23.84 ± 3.29) mm as compare to right side (22.49 ± 2.37) mm. Left femur (55.59 ± 6.41) mm have more distance between greater and lesser trochanter as compare to right one (51.81 ± 5.2). The neck shaft angle is more on left side ($129.85^\circ \pm 5.08$) as compare to right side ($128.13^\circ \pm 7.44$). Surgical neck diameter is more on right side (34.19 ± 4.85) mm as compare to left side (29.86 ± 3.41) mm. The difference between the vertical diameter of right and left side of femoral head was statistically significant ($r=0.42$ & p -value 0.01) while, the transverse diameter of femoral head was found to be nearly significant ($r=0.31$ & p -value 0.09) and that of width of femur is statistically significant when compared to right and left side ($r=0.58$, p -value 0.0007) whereas pearson coefficient and correlation of other parameters (length of neck of femur, distance between greater and lesser trochanter, neck shaft angle and surgical diameter of head of femur)

were found to be significantly insignificant [Table 1].

Table 1: Showing different parameters of right and left side of upper end of femur

Parameters	Side	Number (n)	Max	Min	Mean (mm)	Std. dev	Total mean ± Std. dev	p-value	r-value
Head diameter (vertical)	Right	30	47.55	23.59	40.65	3.6	40.89±4.26	0.01	0.42
	Left	30	48.34	34.13	41.05	3.98			
Head diameter (transverse)	Right	30	49.12	25.11	38.42	4.05	37.96±4.20	0.09	0.31
	Left	30	44.07	26.93	37.32	3.91			
Length of neck	Right	30	35.46	18.65	26.2	4.52	26.14±4.56	0.46	0.13
	Left	30	35.75	18.79	25.76	4.69			
Width of neck	Right	30	28.99	16.59	22.49	2.37	23.20±3.06	0.0007	0.58
	Left	30	34.77	19.24	23.84	3.29			
Distance between greater and lesser trochanter	Right	30	63.22	29.63	51.81	5.2	53.67±7.19	0.24	0.21
	Left	30	73.89	45.89	55.59	6.41			
Neck shaft angle	Right	30	142°	105°	128.13°	7.44	129.03±6.53	0.34	0.18
	Left	30	143°	121°	129.85°	5.08			
Surgical neck diameter	Right	30	44.54	25.53	34.19	4.85	32.05±4.61	0.61	0.09
	Left	30	37.66	24.82	29.86	3.41			

Table 2: Discussion table of different parameters of proximal end of femur

AUTHORS NAMES (Year of study)	Head diameter (Vertical) (mm)	Head diameter (Transverse) (mm)	Length of neck(mm)	Width of neck(mm)	Distance between greater and lesser trochanter	Neck shaft angle (degrees)
Gupta M et al(2022) ^[4]		41.59±3.25	36.06±4.94	27.61±2.71	41.92±3.90	119.08±5.18
Ramchander Siwach(2020) ^[5]		43.95±3.06	37.23±4.65	31.87±2.19		123.5±4.43
Kamath SU et al(2020) ^[7]	44.80±4.20				137.80±6.90	
Minakshi Verma et al(2017) ^[3]	42.32±4.11		44.75±8.097	24.01±3.05		128.90±4.49
Peter Ericson	4.23±0.54 (cm)	4.23±0.33 (cm)				119.44±4.13
Lingamdenne et al(2016) ^[8]						
Present study(2023)	40.89±4.26	37.96±4.20	26.14±4.56	23.20±3.06	53.67±7.19	129.03±6.53

Table 3: Discussion table of different parameters of proximal end of right and left femur

AUTHORS NAMES	Head Diameter(Vertical) (mm)		Head Diameter (Transverse)(mm)		Length of neck(mm)		Width of neck (mm)		Neck shaft angle (degrees)	
	Right	Left	Right	Left	Right	Left	Right	Left	Right	Left
Sengupta (Ghosh) et al ^[9] (2020)	38.56±2.5	38.07±3.43			26.37±2.92	26.12±3.42	28.84±2.71	28.09±2.29	124.53±6.35	126.9±7.67
Kamath SU et al ^[7] (2020)			44.46±3.97	45.16±4.48					137.27±7.23	138.38±6.65
Sengodan et al (2017) ^[10]	42.5±2.8	42.6±2.8					26.9±3.1	28.1±3.1	134.6±4.8	136.2±4.1
Minakshi Verma et al (2017) ^[3]	42.51±3.729	42.11±4.530			44.83±9.094	44.66±6.982	24.15±3.043	23.86±3.092	127.57±4.661	130.3±3.875
Muley Mrunal et al ^[11] (2017)					34.96±7.18	33.42±4.12	29.38±2.5	28.86±3.47		
Mukherjee et al ^[13] (2021)									124.91°±5.88°	123.33°±6.47°
Present study (2023)	40.65±3.6	41.05±3.98	38.42±4.05	37.32±3.91	26.2±4.52	27.6±4.69	22.49±2.37	23.84±3.29	128.13±7.44	129.85±5.08

DISCUSSION

[Table 2]: Discussion table of different parameters of proximal end of right and left femur

[Table 3]: Discussion table of different parameters of proximal end of femur

Based on research on projection, it was calculated that demand for primary total hip arthroplasties will increase by 174% by 2030.^[5]In India also there is many folds increase in total hip arthroplasties during last years. There is also increase in road traffic

accident and diseases of hip joint. In some of the above cases joint fixation and surgeries are required. If joint fixation with mismatch implants has done then it may cause complications like infection-free detachment, uneven force distribution, uneasiness, slight movement of the inserted stem and bone resorption.^[5] Therefore, proper measurements of proximal end of femur can provide better tool for designing implants and prosthesis to decrease post-operative complications and also for promising outcome of surgeries.^[6]

The present study revealed vertical diameter (40.89±4.26mm) is less than the study of Kamath SU et al,^[7] (44.80±4.20 mm) but it is comparable to studies of Minakshi Verma et al,^[3] (42.32±4.11mm) and Peter Ericson Lingamdenne et al,^[8] (4.23±0.54cm). The transverse diameter (37.96±4.20mm) of head is less than studies of Gupta M et al,^[4] (41.59±3.25mm), Ramchander Siwach,^[5] (43.95±3.06mm) and Peter Ericson Lingamdenne et al,^[8] (4.23±0.33cm) [Table 2]. The length of neck of femur (26.14±4.56 mm) in present study is less than Gupta M et al,^[4] (36.06±4.94mm), Ramchander Siwach,^[5] (37.23±4.65 mm) and Minakshi Verma et al,^[3] (44.75±8.097mm), while the width of neck of femur (23.20±3.06mm) is comparable to Minakshi Verma et al,^[3] (24.01±3.05 mm) but less than the study of Gupta M et al,^[4] (27.61±2.71mm), Ramchander Siwach (31.87±2.19mm).^[5] These differences in parameters may be due to regional variation [Table 2].

The distance (53.67±7.19mm) between lesser and greater trochanter in present study is more as compare to Gupta et al,^[4] (41.92±3.90mm) but less than the study of Kamath et al^[7] (137.80±6.90mm). The present study showed that neck shaft angle (129.03±6.53) is more as compare to other studies and it is comparable to study of Minakshi et al,^[3] (128.90±4.49) and Mukherjee et al (123.33°±6.47° of left femur and that of right femur 124.91°±5.88°) [Table 2].^[9-13]

The vertical and horizontal diameters of right and left femur are comparable to each other in present study. The vertical diameter of right and left femur are comparable to study of Minakshi et al,^[3] and Sengodan et al,^[10] but more than the study of Sengupta et al.^[9] The transverse diameter of head is less than Kamath et al.^[7] Like other parameters the length and width of right and left femur is comparable to each other. The length of neck is less than the study of Minakshi et al,^[3] and Muley Mrunal et al,^[11] but comparable to the study of Sengupta et al.^[9] The width of neck on right and left side of femur is comparable to Minakshi et al,^[3] but less than the study of Sengupta et al,^[9] Muley Mrunal et al,^[11] Sengodan et al [Table 3].^[10]

The present study measured the distance between greater and lesser trochanter of femur (51.8±5.2mm and 55.59±6.41mm on right and left side respectively) which is required for formation of proper fitting implants of femur. The surgical neck diameter (34.19±4.85mm and 29.86±3.41mm) of right and left side of head of femur were also measured. We do not find any study which describes the above two parameters. Therefore, these

measurements may further add proper accuracy of implant in total hip arthroplasty.

CONCLUSION

The present study may provide and add data for implant and prosthesis for head of femur in case of arthroplasties in Garhwal region of Uttarakhand. It also emphasize that there are racial and regional variation in parameters of head of femur.

Acknowledgement: The authors thank Dr. Abhinav Kumar (Post graduate resident) of Department of Anatomy for photography. The authors acknowledge the contribution of persons who donated their every body parts for teaching, learning and research purpose to serve mankind.

REFERENCES

1. Standring S: Gray's Anatomy: The Anatomical Basis of Clinical Practice. Elsevier Health Sciences, USA; 2016.
2. Bidmos MA: Stature reconstruction using fragmentary femora in South Africans of European descent. *J Forensic Sci.* 2008, 53:1044-1048.
3. Verma M, Joshi S, Tuli A, Raheja S, Jain P, Srivastava P. Morphometry of proximal femur in Indian population. *Journal of clinical and diagnostic research: JCDR.* 2017 Feb;11(2):AC01.
4. Gupta M, Devadas D, Sahni C, Nayak A, Tiwari PK, Mishra A. Morphometric analysis of the proximal femur with its clinical correlation in Eastern Uttar Pradesh Region. *Cureus.* 2022 Sep 4;14(9).
5. Siwach R. Anthropometric study of proximal femur geometry and its clinical application. *Annals of the National Academy of Medical Sciences (India).* 2018 Oct;54(04):203-15.
6. Rawal B, Ribeiro R, Malhotra R, Bhatnagar N: Anthropometric measurements to design best-fit femoral stem for the Indian population. *Indian J Orthop.* 2012, 46:46-53.
7. Kamath SU, Agarwal S, Austine J: Morphology of proximal femur in South-West Coast of India. *Malays Orthop J.* 2020, 14:143-150.
8. Lingamdenne PE, Marapaka P, Lingamdenne PE: Examination evaluation and statistical analysis of human femoral anthropometry in Hyderabad and Secunderabad regions, India. *Indian J Clin Anat Physiol.* 2016, 3:427-432.
9. Sengupta I, Mahato M, Sengupta G, Chattopadhyay JC: A morphometric study of the proximal end of dry adult femora. *Int J Anat Res.* 2020, 8:7799-7804.
10. Sengodan VC, Sinmayanatham E, Kumar JS: Anthropometric analysis of the hip joint in South Indian population using computed tomography. *Indian J Orthop.* 2017, 51:155-161.
11. Muley M, Bhuiyan P. Morphometric study of neck of dry adult femora. *Int J Anat Res.* 2017;5(3.2):4317-20.
12. Kurtz S, Ong K, Lau E, Mowat F, Halpern M. Projections of primary and revision hip and knee arthroplasty in the United States from 2005 to 2030. *Jbjs.* 2007 Apr 1;89(4):780-5.
13. Mukherjee B, Sadhu A, Majumdar S. Evaluation of neck-shaft angle of dry femora in the gangetic region of West Bengal. *National Journal of Clinical Anatomy.* 2021 Jul 1;10(3):148-54.